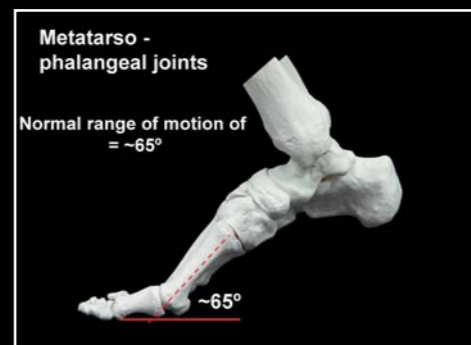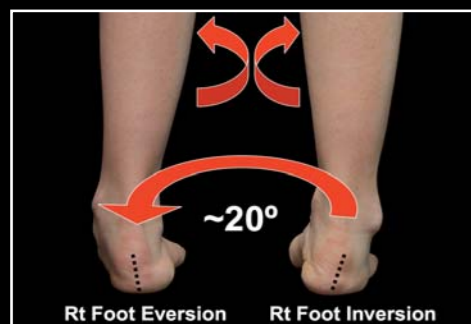


# Thinking Straight (Ahead)

By Howard J. Dananberg, DPM

This will be the first article of a series that describes a medical, mechanical and manipulative approach to management of sagittal plane pathomechanics. Modern podiatric biomechanics has previously been centered on frontal/transverse motion evaluation since the earliest days of its development in the late 1960's.<sup>1</sup> The use of rear foot posting became the most common type of orthotic therapy as it was believed that all pathology stemmed from excessive frontal plane motion at the subtalar joint. While results seemed acceptable, many found frustration with this as their only approach, and many conditions failed to respond to this type of treatment. By combining with the Vasyli family of companies, a new product line (Vasyli-Dananberg) will be developed that will add the tool of sagittal plane treatment to the orthotic therapy management.

When a subject steps forward, a complex series of inter-limb actions occur in sequence, creating what we have come to understand as the gait cycle. Viewing this in classic podiatric fashion from the rear view (ie, hallway perspective), the dynamics of the sagittal plane become hidden. For instance, the combination of reduced hip extension with simultaneous flexion of the knee is simply not perceptible. However, once the observer steps to a point of view when side motion becomes visible, then suddenly a new world opens to the kinetic process of human walking. When one only considers the rear view, the combined amount of foot level motion of inversion-eversion and internal-external rotation are well below 20°. However, considering the normal range of motion of 65° of only the metatarso-phalangeal joints, then the magnitude of sagittal plane motion starts to be evident. When the sagittally based pivotal sites of the heel and ankle joint are coupled with extension mechanics of the hip, the amount of motion through the sagittal plane becomes a dramatic increase as compared to only the frontal-transverse (and traditional) perspective. Not viewing the sagittal plane is akin to ignoring its presence. Failure of normal sagittal plane pivotal motion to occur in a timely fashion would require force dissipation through the remaining planes. What we have traditionally called "excessive midstance



pronation" or "late phase pronation" is the REPRESENTATION of the foot's dispersion of these forces through the transverse/frontal plane.<sup>2</sup> Treatment outcomes improve substantially when the bulk of the motion is included in the evaluation and addressed in the treatment process.<sup>3</sup>

## Sagittal plane restriction:

When we step forward, the mechanical action of the swing limb actually pulls the body. The swing limb, therefore acts upon the weight bearing or trailing limb. For normal motion to occur, the hip and knee move towards extension, while the foot permits sagittally based rotation to occur. This allows for the torso to remain in the erect position, while the trailing limbs naturally (and passively) extends out from under the hip joint. Should failure of any of the sites of sagittal plane motion occur, then a series of compensatory motions would be required. The primary locations for sagittal plane restriction are as follows:

1. Functional hallux limitus (Fhl)
2. Structural hallux limitus (Shl)
3. Ankle equinus (AE)
4. Forefoot Equinus (FE)
5. Hip joint arthritis
6. Forefoot pain/midfoot pain

## 1. Functional hallux limitus:

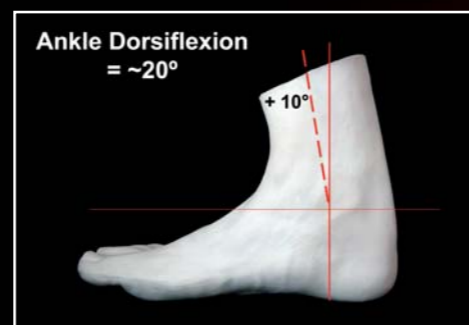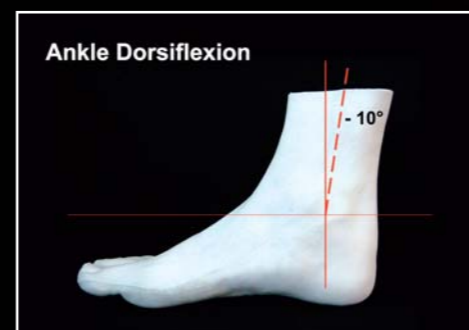Functional hallux limitus or Fhl, is a strictly dynamic condition in which normal motion exists at the 1st metatarso-phalangeal (MTP) joint during non-weight bearing examination. When loaded and strictly during the single support phase of the gait cycle, however, no range of motion is available. This paradox is what defines Fhl. There is often no pain associated with the 1st MTP Joint and patients will rarely, if ever, complain about symptoms at this location. They will, however, complain about pain as the foot and more proximal structures are repeatedly stressed during the compensatory process.<sup>4</sup> Since Fhl is strictly a functional disorder, the use of orthotic modifications are required for management. This is the basic principle around the Vasyli-Dananberg device. By using a variety of removable plugs on the inferior surface of the 1st metatarsal head, varying degrees of

1st metatarsal head plantarflexion can be achieved, thus alleviating the potential for Fhl to develop. The practical application of these modifications will be discussed in later articles.

## 2. Structural hallux limitus

Structural hallux limitus or Shl represents the degenerative joint process involving the 1st MTP joint. Motion can be partially or completely (hallux rigidus) restricted. Classic treatment of Shl involved the reduction of motion at the 1st MTP joint, with the basic reasoning that "it hurts to move, so let's prevent the motion". To think about Shl in another way, however, opens up a new way to approach this painful condition, and thus reverse (partially or completely) the degenerative process. One can think of Shl as hurting "because it doesn't move when it should". In other words, Shl is a RESULT of repetitive strain applied to the 1st MTP joint because the precursor to Shl is Fhl. So, the joint fails to move at the time when maximum motion is required. Jamming of the joint results with eventual structural changes developing as the body repeatedly tries to repair the chronically injured site.<sup>5</sup> Use of the Vasyli-Dananberg device is one part of the treatment equation, and the addition of other manual methods can enhance this effect. These will be covered in future articles.

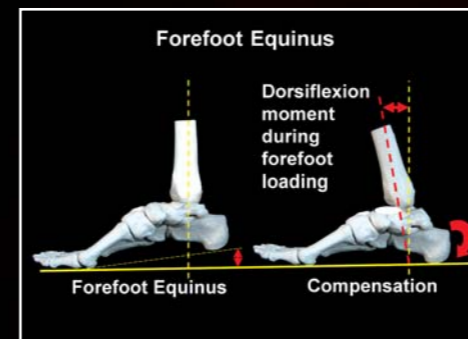
## 3. Ankle equinus



During the normal gait cycle when one limb is swinging, there is a comparable time when the opposite foot is flat on the support surface. Since the body continues to move over the weight bearing foot, there must exist a mechanism to allow for this to occur. This is why the ankle joint can dorsiflex. It permits forward motion of the body over the fully planted foot. Restrictions to ankle joint dorsiflexion have been commonly referred to as ankle equinus, and it has been previously referenced to as one of the most "pronation" related deforming entities

present during foot function. Ankle equinus was previously managed via a program of vigorous stretching and or surgery to lengthen the Achilles tendon. Future articles will specifically denote how manipulation of the fibula and talus can restore motion to the ankle joint. Other neuromuscular affects also occur and these will be described, along with recommendations for a large variety of common problems of the foot and ankle related to the equinus state.<sup>6</sup>

## 4. Forefoot equinus



Forefoot equinus is another way to view the deformity associated with cavus feet. In a forefoot equinus situation, the level of the metatarsal heads is essentially "lower" than the level of the heel. In affect, it causes a dorsiflexion moment to be applied to the ankle joint, as the forefoot loads during the gait cycle. A simple way to visualize this problem is to think of it as making the body walk "uphill" all the time. Elevation of the heel with the correct forefoot modifications is the most straightforward approach to management.

## 5. Hip joint arthritis

Degenerative disease of the hip is a common orthopedic problem. Some stress reduction via foot orthotic management may be helpful, but primary arthritis of the hip joint may ultimately require surgical management. Patients who are unable to extend their hips during the normal gait cycle can be helped if lack of motion is related strictly to some type of compensatory process.

## 6. Forefoot or midfoot pain

Chronic pain in the forefoot (including corns and callouses) or pain in the midfoot due to degenerative joint disease prevent normal forefoot loading and the ability to raise the heel about this forefoot pivot. Careful diagnosis and treatment are required to manage this type of patient, and surgery may ultimately be required for positive long-term outcome. Certain types of midfoot pain are related to restriction in joint mobility, and manipulation/mobilization can often be extraordinarily successful. These techniques will be described in detail both in future articles as well as on the Vasyli website in future web based lecture programs.

In conclusion, one or multiple entities can exist that alter the ability of the body to step over the foot during the single support

phase of the gait cycle. These in turn create compensations within the foot and more proximal structures that cause or perpetuate many painful pathological conditions ranging from plantar fasciitis, to knee pain to chronic lower back pain. Localized treatments can be very effective, but relieving the repetitive strain present during the gait cycle is what prevents recurrence. The purpose of this series is to detail how these compensations occur and what are the best available methods of treatment.

**VASYLI**  
**THINKTANK**  
...from head to foot

## ARTICLE #1

**Howard Dananberg, renowned worldwide for development of the concepts of Functional Hallux Limitus and the relationship of gait style to Chronic Lower Back Pain...**

### REFERENCES:

1. Root, M., Weed, J & Orien, W 1977 *Abnormal and Normal Function of the Foot, Clinical Biomechanics Corp., Los Angeles, CA*
2. Wernick, Justin, and Dananberg, Howard J. 1988 *Secondary Active Retrograde Pronation an the Ideology to Overuse Injuries in Podiatry Tracts, October, Data Trace Medical Publishers, Baltimore*
3. Dananberg, HJ, Gulliano, M, "Chronic Lower Back Pain And It Response to Custom Foot Orthoses", *Journal of the American Podiatric Medical Association, 89:3 March, 1999 pp109-117*
4. Dananberg, Howard J. "Functional Hallux Limitus and Its Relationship to Gait Efficiency" in *The Journal of the American Podiatric Medical Association; November 1986*
5. Dananberg, HJ, "A New Protocol for Understanding Hallux Limitus" oral presentation, *American Podiatric Medical Association Annual Meeting, Las Vegas, August 9, 2006*
6. Dananberg, HJ, Shearstone, J, Gulliano, M "Manipulation Method for the Treatment of Ankle Equinus," *Journal of the American Podiatric Medical Association, 90:8 September, 2000 pp 385-389*

www.vasyli.com/medical

